

**Telemedicine Clinic**  
*Rattanakiri*  
**Referral Hospital**  
**June 2005**

**Report and photos compiled by Rithy Chau, SHCH Telemedicine**

On Thursday, June 23, 2005, Rattanakiri Referral Hospital (RRH) staff began their TM clinic. PA Rithy Chau was not present during this month clinic. The patients were examined and the data were transcribed along with digital pictures of the patient, then transmitted (except for a few follow-up patients who came for medication refills and/or further instruction on referring to PP) and received replies from their TM partners in Boston and Phnom Penh.

The following day, Friday, June 24, 2005, the TM clinic opened again to receive the same patients for further evaluation, treatment and management. Finally, the data for treatment and management would then be transcribed and transmitted to the PA Rithy Chau at SHCH who compiled and sent for website publishing.

**The followings detail e-mails and replies to the medical inquiries communicated between TM clinic at RRH and their TM partners in Phnom Penh and Boston :**

**From:** Kiri Hospital [mailto:kirihospital@yahoo.com]  
**Sent:** Thursday, June 16, 2005 3:38 PM  
**To:** Rithy Chau; jmiddleb@camnet.com.kh; Cornelia Haener; Ruth Tootill; Brian Hammond; Paul Heinzelmann; Kathleen M. Kelleher; Joseph Kvedar  
**Subject:** The Next TM clinic at Rattanakiri

Dear All,

Please be informed that the next TM clinic at Rattanakiri Referral Hospital will be held on Thursday, June 23, 2005 beginning at 8:00am local time for one full day. We expect to enter and transmit the patient data to those of you at SHCH and at Partner in Boston that evening.

Please try to respond before noontime the following day, Friday, June 24, 2005. The patients will be asked to return to the hospital that afternoon on Friday to receive treatment along with a follow up plan or referral.

Thank you very much for your cooperation and service.

Best regards,

Channarith Ly

**From:** Kiri Hospital [mailto:kirihospital@yahoo.com]

**Sent:** Thursday, June 23, 2005 4:47 PM

**To:** Rithy Chau; jmiddleb@camnet.com.kh; Brian Hammond; Paul Heinzelmann; Kathleen M. Kelleher; Joseph Kvedar; Rithy Chau

**Cc:** Ed & Laurie Bachrach; HealthNet International; Bernie Krisher; Noun SoThero; Fil B. Tabayoyong

**Subject:** Rattanakiri provincial hospital TM clinic patient TR#00120

Dear All,

There are 5 new case of this month. Here is the patient TR#00120 and his photos.

Best regards,

Channarith

---

### **Rattanakiri Provincial Hospital Telemedicine Clinic with Sihanouk Hospital Center of HOPE and Partners in Telemedicine**



**Patient:** TR#00120,36M,Village I

**Chief Complaint:** right hip joint pain for 2 years on motion

**HPI:** 36 man , has slightly presented with right hip pain since 2003 and he treated with prednisolone 0.5mg 1tab po tid x3 weeks , PNC250 mg 2 tab po tid x 3 weeks , ibuprofen 400 mg 1 tab po bid x 15 days at private clinic ,he did slightly relieve . At 6 months later, his symptoms strongly reappeared the right hip join pain with limped gait association with muscle atrophy of right calf and a bit number on right calf , and then he was treating with ATENERIN 1 Amp qd / 2 days for 3weeks and DICLOFENAC 1 vial IM bid x 3 weeks at private clinic, He did no relieve and has still had previous pain. no hot on right hip and no pain when cold , no edema of hip .no fever , no headache , no n/v .

**PMH/SH:**

**Social Hx:** cigarette smoking x 3 years ago , alcohol off and on.

**Allergies:** none

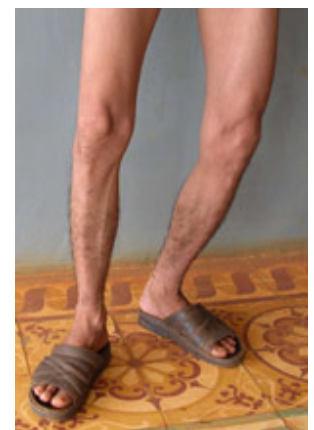
**Family Hx:** unremarkable

**ROS:**

**PE:**

**Vital Signs:** BP100/70mmhg P70/mn R20/mn T37.5 Wt 34kg

**General:** alerted and oriented



**HEENT:** no otitis , no blurry vision ,no ptosis ,no sore throat .

**Chest: lungs :** clear both sides , no crackle ,no rhonchi  
Heart : no murmur ,HRR normal.

**Abdomen:** soft , no mass , no organomegally , active BS .

**Musculoskeletal:** no edema of femoral head , no hot pain on femoral head , limped gait , waddling gait ,he can not heel to toe to straight line because pain ,adduction with flexion is right hip pain , abduction with flexion no pain , rotation with flexion : inward pain , outward pain off and on ,muscle atrophy of right calf and thigh , standing position : inward and outward are pain .

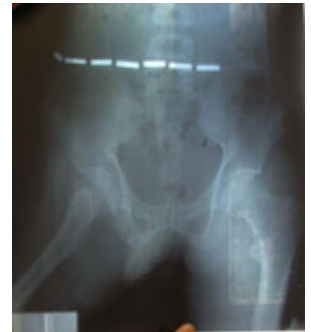**Neuro:** sensory is intact,right leg of motor is a bit weaker than left leg motor

**GU:none**

**Rectal:** none

**Previous Lab/Studies:** none

**Lab/Studies Requests:** x-ray of femoral head , ca<sup>2+</sup> :6.8 ,Mg<sup>2+</sup> : 2.4 , K<sup>+</sup> : 5.6 , Na<sup>+</sup> : 160.1, wbc : 4600,RBC:4150000, hb: 14.o ,Htc :42 ,Hexagon TB testing negative , ASLO : Positive ,



**Assessment:** 1.TB arthritis 2.osteochondritis 3.osteoarthritis

**Plan:** 1.anti TB drugs for x 6 months by national program guideline .  
2.VIT B1 , B 6, B12 1 tab po for x one month  
3.

**Comments/Notes:** please , give a good idea

**Examined by:** Dr kok san **Date:** 23/6/05

Please send all replies to [kirihospital@yahoo.com](mailto:kirihospital@yahoo.com) and cc: to [tmed\\_rithy@online.com.kh](mailto:tmed_rithy@online.com.kh) .

*The information transmitted in this e-mail is intended only for the person or entity to which it is addressed and may contain confidential and/or privileged material. Any review, retransmission, dissemination or other use of or taking of any action in reliance upon, this information by persons or entities other than the intended recipient is prohibited. If you received this e-mail in error, please contact the sender and delete material from any computer.*

**From:** Rithy-chau [mailto:[tmed\\_rithy@online.com.kh](mailto:tmed_rithy@online.com.kh)]

**Sent:** Thursday, June 23, 2005 5:03 PM

**To:** 'Kiri Hospital'; 'jmiddleb@camnet.com.kh'; 'Brian Hammond'; 'Paul Heinzelmann'; 'Kathleen M. Kelleher'; 'Joseph Kvedar'; 'Rithy Chau'

**Cc:** 'Ed & Laurie Bachrach'; 'HealthNet International'; 'Bernie Krisher'; 'Noun SoThero'; 'Fil B. Tabayoyong'

**Subject:** RE: Rattanakiri provincial hospital TM clinic patient TR#00120

Dear All,

Please take note that in the hip x-ray sent to you by TM RRH staff, Dr. Kok San, included large dashed line across his waist line probably due to an artifact worn by the patient to protect him from bad fortune and protect him from unwanted spirits that may cause him to be ill.

Dr. San/Channarith, can you please confirm my reading for this part of the image to the other physicians?

Thank you and best regards,  
Rithy

**From:** Fiamma, Kathleen M. [mailto:KFIAMMA@PARTNERS.ORG]  
**Sent:** Friday, June 24, 2005 3:06 AM  
**To:** kirihospital@yahoo.com  
**Cc:** tmed\_rithy@online.com.kh  
**Subject:** FW: Rattanakiri provincial hospital TM clinic patient TR#00120

-----Original Message-----

**From:** Tan, Heng Soon, M.D.  
**Sent:** Thursday, June 23, 2005 11:12 AM  
**To:** Fiamma, Kathleen M.  
**Subject:** RE: Rattanakiri provincial hospital TM clinic patient TR#00120

The quality of the hip xray is poor. I believe there is sclerotic and cystic changes on the right femoral head and acetabulum with narrowed joint space consistent with osteoarthritis. Is there history of trauma to explain single joint arthritis? He is too young to just have degenerative osteoarthritis. Previous use of systemic steroids may lead to avascular necrosis of single joint, but he does not have asthma or other systemic illness requiring oral steroids. Congenital hip dysplasia usually affects both joints. Tuberculosis of single joint is a good thought but is there evidence for this? His TB skin test is negative. There is no sign of joint inflammation by exam. The definitive test requires aspiration of the joint and biopsy of synovium to look for leukocytes in synovial fluid and acidfast bacilli by smear [may be negative] and by culture [80% yield]. He should consult an orthopedic surgeon. The ideal treatment for him is a total hip replacement. If that is not available, then use of NSAID and physical therapy to maintain strength may keep him functional.

Heng Soon Tan, M.D.

**From:** Jack Middlebrooks [mailto:jmiddleb@camnet.com.kh]  
**Sent:** Friday, June 24, 2005 8:25 AM  
**To:** 'Kiri Hospital'; 'Rithy Chau'; 'Brian Hammond'; 'Paul Heinzelmann'; 'Kathleen M. Kelleher'; 'Joseph Kvedar'; 'Rithy Chau'  
**Cc:** 'Ed & Laurie Bachrach'; 'HealthNet International'; 'Bernie Krisher'; 'Noun SoThero'; 'Fil B. Tabayoyong'  
**Subject:** RE: Rattanakiri provincial hospital TM clinic patient TR#00120

Dear Dr. San:

I agree with your assessment. In addition to TB meds, I would also treat the patient's pain with paracetamol 500 mg BID.

I will also share this case with the SHCH orthopedic surgeon today and will send his opinion later if he has an additional comments.

Jack

**From:** Kiri Hospital [mailto:kirihospital@yahoo.com]  
**Sent:** Thursday, June 23, 2005 5:16 PM  
**To:** Rithy Chau; jmiddleb@camnet.com.kh; Brian Hammond; Paul Heinzelmann; Kathleen M. Kelleher; Joseph Kvedar; Rithy Chau; Cornelia Haener; Ruth Tootill  
**Cc:** Ed & Laurie Bachrach; Bernie Krisher; Noun SoThero; Fil B. Tabayoyong  
**Subject:** Rattanakiri provincial hospital TM clinic patient CL#00121

Dear All,

Here is the patient CL#00121 and there will be one photo to be sent later.

Best regards,

Channarith

---

**Rattanakiri Provincial Hospital Telemedicine Clinic with  
Sihanouk Hospital Center of HOPE and Partners in Telemedicine**



**Patient:** CL#00121,31f,villageIII

**Chief Complaint:** a small mass on neck for 8 years

**HPI:** she presented with a small mass on neck which developed slowly and the mass moved the saliva swallowing ,she felt the mass which compressed on her throat when swallowed the saliva and the anther things without the exophthalmia , palpitation and tremor o f extremities .no ptosis ,no tinnitus ,no HA ,no sob , no vertigo ,no fever .she did not took the anti drugs to gland thyroid.

**PMH/SH:**

**Social Hx:** no EOTH

**Allergies:** no

**Family Hx:** just sister has the mass on neck

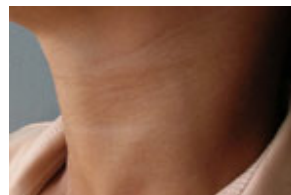**ROS:**

**PE:**

**Vital Signs:** BP90/60mmhg P68/mn R23 T37.5 Wt 42.5

**General:** alerted and oriented

**HEENT:** size :2x3 cm, soft mass on palpation , no bruit , no multiple nodular ,no JVD ,no solid ,  
swallowed mobile .



**Chest:** lungs: clear both sides  
heart : no murmur ,HRR normal

**Abdomen:** soft ,no diarrhea ,no organomegaly ,active BS , no mass .

**Musculoskeletal:** unremarkable

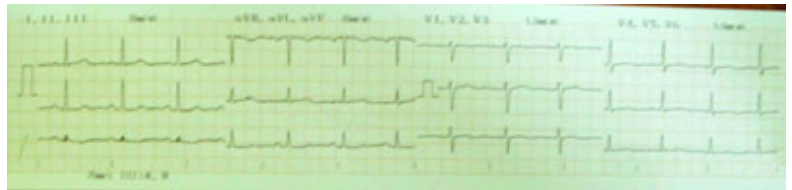
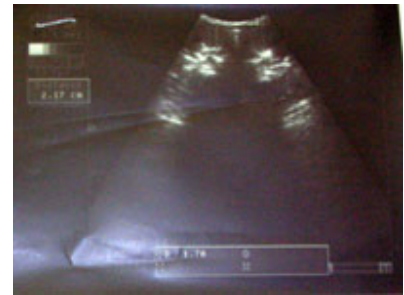**Neuro:** motor and sensory are intact

**GU:** none

**Rectal:** none

**Previous Lab/Studies:**

**Lab/Studies Requests:** EGK, ultrasound : a bid enlarge volume of gland thyroid , regular margin with homogenous echotexture .right lobe size:1.7 cm .left lobe size :2.1 cm .CBC :wbc:5400/mm<sup>3</sup>,Htc:36% , hb:13.1g/dl,RWC:3500000/mm<sup>3</sup>



**Assessment:** 1.hypothyroidism 2.hyperthyroidism 3. r/o nodular goiter 4. r/o tonsillitis

**Plan:** 1.check free T4 ,T3 and TSH at SHCH IN PP .

**Comments/Notes:** PLEASE ,give a good idea

**Examined by:** Dr kok san **Date:** 23/6/05

Please send all replies to [kirihospital@yahoo.com](mailto:kirihospital@yahoo.com) and cc: to [tmed\\_rithy@online.com.kh](mailto:tmed_rithy@online.com.kh) .

*The information transmitted in this e-mail is intended only for the person or entity to which it is addressed and may contain confidential and/or privileged material. Any review, retransmission, dissemination or other use of or taking of any action in reliance upon, this information by persons or entities other than the intended recipient is prohibited. If you received this e-mail in error, please contact the sender and delete material from any computer.*

**From:** Jack Middlebrooks [mailto:jmiddleb@camnet.com.kh]

**Sent:** Friday, June 24, 2005 8:57 AM

**To:** 'Kiri Hospital'; 'Rithy Chau'; 'Brian Hammond'; 'Paul Heinzelmann'; 'Kathleen M. Kelleher'; 'Joseph Kvedar'; 'Rithy Chau'; 'Cornelia Haener'; 'Ruth Tootill'

**Cc:** 'Ed & Laurie Bachrach'; 'Bernie Krisher'; 'Noun SoThero'; 'Fil B. Tabayoyong'

**Subject:** RE: Rattanakiri provincial hospital TM clinic patient CL#00121

Dear Dr. San:

Helpful elements in a history for thyroid disease include changes in weight, changes in mood, changes in hair and skin, changes in temperature tolerance, and a description of the menstrual cycle. In the physical exam, testing reflexes can also be helpful.

I agree with your plan to measure thyroid function tests.

With best regards,

Jack

**From:** Fiamma, Kathleen M. [mailto:KFIAMMA@PARTNERS.ORG]  
**Sent:** Saturday, June 25, 2005 12:46 AM  
**To:** kirihospital@yahoo.com  
**Cc:** tmed\_rithy@online.com.kh  
**Subject:** FW: Rattanakiri provincial hospital TM clinic patient CL#00121

-----Original Message-----

**From:** dsands@bidmc.harvard.edu [mailto:dsands@bidmc.harvard.edu]  
**Sent:** Thursday, June 23, 2005 6:45 PM  
**To:** Fiamma, Kathleen M.  
**Subject:** RE: Rattanakiri provincial hospital TM clinic patient CL#00121

It's very hard for me to understand your case report. Where is the mass it located (I don't see it on the images)? What does it feel like? Is it painful to touch? Has it changed over time? Is she sure it has only been there eight year?

Why do you think she might have hyper- or hypothyroidism? I don't find anything in your case report history of examination to suggest these diagnoses. Why did you think she might have tonsillitis? Does she have a sore throat?

She does have a rapid respiratory rate (23). I would suggest you obtain a chest x-ray.

If the mass is not tender, not growing, does not feel rock hard (like a tumor), it's probably nothing to worry about. It is likely either a fibrosed lymph node, a benign thyroid nodule (but it was not seen on ultrasound), or a benign (perhaps congenital) cyst, like a branchial cleft cyst.

Other than the x-ray, I think it's fine to send a TSH and free T4. You might also consider a CT scan of the neck.

Thanks.

- Danny Daniel Z. Sands, MD, MPH V: (617) 667-1510  
\_\_\_/ Center for Clinical Computing  
(\_\_ Beth Israel Deaconess Medical Center  
\_\_\_) Harvard Medical School <http://cybermedicine.caregroup.harvard.edu/dsands>

**From:** Kiri Hospital [mailto:kirihospital@yahoo.com]

**Sent:** Thursday, June 23, 2005 5:29 PM

**To:** Rithy Chau; jmiddleb@camnet.com.kh; Brian Hammond; Paul Heinzelmann; Kathleen M. Kelleher; Joseph Kvedar; Rithy Chau; Cornelia Haener; Ruth Tootill

**Cc:** Ed & Laurie Bachrach; Bernie Krisher; Noun SoThero; Fil B. Tabayoyong

**Subject:** Rattanakiri provincial hospital TM clinic patient CL#00122

Dear All,

Here is the patient CL#00122 and her photos .

Best regards,

Channarith

---

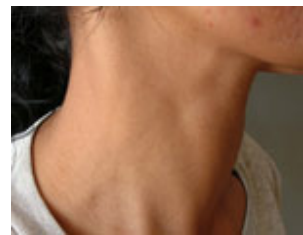**Rattanakiri Provincial Hospital Telemedicine Clinic with  
Sihanouk Hospital Center of HOPE and Partners in Telemedicine**



**Patient:** CL#00122,33F,VILLageIII

**Chief Complaint:** a Mass of neck for x 10 years

**HPI:** 33F , Presented with a slightly development of a mass on neck with palpitation off and on and weigh loss,especially palpitation on exertion without exophthalmia ,no tremor of extremities ,no ptosis , no headache ,no tinnitus , no blurry vision , no fever , she did took the anti drugs gland thyroid .



**PMH/SH:**

**Social Hx:** no smoking ,no alcohol

**Allergies:** non

**Family Hx:** young sister has a small mass on neck

**ROS:**

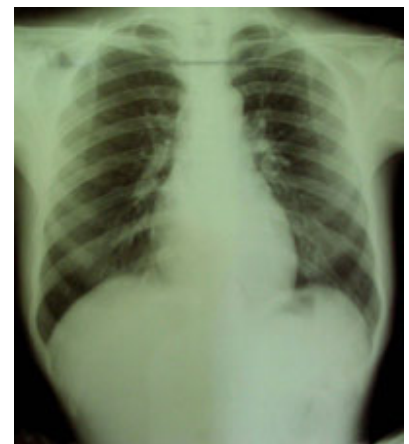**PE:**

**Vital Signs:** BP100/0mmhg P68/mn R20 T36.5 Wt 43kg

**General:** alerted and oriented

**HEENT:** size :3x4cm , soft on palpation ,right lobe is more than left lobe, swallow mobile , no bruit on auscultation , no multiple nodular on palpation , no hot skin on mass , no JVD , no solid of mass

**Chest:** lungs :clear both sides , no crackle no rhonchi  
heart : no murmur , HRR normal .





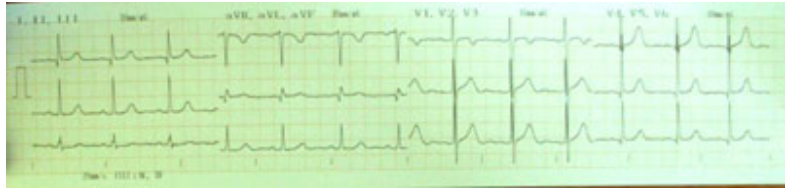**Abdomen:** soft , no mass , no diarrhea ,no organomegally, active BS

**Musculoskeletal:** unremarkable

**Neuro:** motor and sensory are intact

**GU:** none

**Rectal:** none

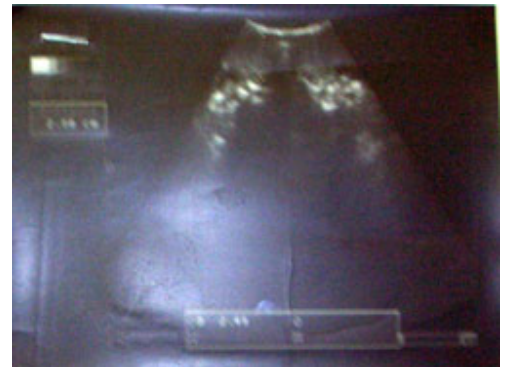

**Previous Lab/Studies:**

**Lab/Studies Requests:** EGK ,ultrasound :a little enlarge volume of both lobe and regular margin , homogenous echotexture , right lobe size:2.8cm ,left lobe size:2.4cm .chest -x-ray .

**Assessment:** 1.hypothyroidism 2.hyperthyroidism 3. r/o nodular goiter

**Plan:** 1.check free T4 ,T3 and TSH at SHCH 2. Atenolol 50 mg 1/4 tab po qd for 14days



**Comments/Notes:** please, give a good idea

**Examined by:** Dr kok san

**Date:** 23//6/05

Please send all replies to [kirihospital@yahoo.com](mailto:kirihospital@yahoo.com) and cc: to [tmed\\_rithy@online.com.kh](mailto:tmed_rithy@online.com.kh) .

*The information transmitted in this e-mail is intended only for the person or entity to which it is addressed and may contain confidential and/or privileged material. Any review, retransmission, dissemination or other use of or taking of any action in reliance upon, this information by persons or entities other than the intended recipient is prohibited. If you received this e-mail in error, please contact the sender and delete material from any computer.*

**From:** Jack Middlebrooks [mailto:jmiddleb@camnet.com.kh]

**Sent:** Friday, June 24, 2005 9:04 AM

**To:** 'Kiri Hospital'; 'Rithy Chau'; 'Brian Hammond'; 'Paul Heinzelmann'; 'Kathleen M. Kelleher'; 'Joseph Kvedar'; 'Rithy Chau'; 'Cornelia Haener'; 'Ruth Tootill'

**Cc:** 'Ed & Laurie Bachrach'; 'Bernie Krisher'; 'Noun SoThero'; 'Fil B. Tabayoyong'

**Subject:** RE: Rattanakiri provincial hospital TM clinic patient CL#00122

Dear Dr. San:

I agree with your plan.

Jack

-----Original Message-----

From: Cusick, Paul S.,M.D. [mailto:PCUSICK@PARTNERS.ORG]

Sent: Friday, June 24, 2005 10:05 AM

To: tmed\_rithy@online.com.kh  
Cc: kirihospital@yahoo.com  
Subject: RE: Rattanakiri provincial hospital TM clinic patient CL#00122

You are describing a young woman who has a possible right thyroid enlargement with intermittent symptoms of hyperthyroidism.

She likely has had intermittent symptoms described by Dr Kok San and right thyroid enlargement for 10 years. You can use atenolol in low doses as needed to try to suppress tachycardia.

Diagnostically, having a TSH, T3 and Free T4 would be helpful. It is not clear that she has a palpable goiter or nodule from your exam and the thyroid ultrasound does not indicate a nodule or enlargement of the gland.

Hashimoto's thyroiditis (autoimmune) or Graves without extrathyroid manifestations.

Are her reflexes brisk?

Depending on the level of hyperthyroidism, she may require chemical prophylaxis (using atenolol for tachycardia) or thyroid inhibitor medications (methimazole or propylthiouracil) or she may require thyroid ablation with radioactive iodinated material followed by thyroid hormone replacement if needed)

Long term excess thyroid hormone increased her risk for osteoporosis and needs to be addressed.

Let me know what you determine.

Paul Cusick

**From:** Cornelia Haener [mailto:cornelia\_haener@online.com.kh]  
**Sent:** Friday, June 24, 2005 12:06 PM  
**To:** 'Jack Middlebrooks'; 'Kiri Hospital'; 'Rithy Chau'; 'Brian Hammond'; 'Paul Heinzelmann'; 'Kathleen M. Kelleher'; 'Joseph Kvedar'; 'Rithy Chau'; 'Ruth Tootill'  
**Cc:** 'Ed & Laurie Bachrach'; 'Bernie Krisher'; 'Noun SoThero'; 'Fil B. Tabayoyong'  
**Subject:** RE: Rattanakiri provincial hospital TM clinic patient CL#00122

Dear all,

I am sorry that I will not be able to contribute today. New software has been set up on my computer, and I am not able to open your documents and images anymore. I hope that our IT staff will be able to fix that problem. If you have a surgical problem today, please mention it directly in your email. Then I will see, if I can have a look on Dr. Jack's computer.

Thanks  
Cornelia

**From:** Kiri Hospital [mailto:kirihospital@yahoo.com]  
**Sent:** Thursday, June 23, 2005 4:53 PM  
**To:** Rithy Chau; jmiddleb@camnet.com.kh; Brian Hammond; Paul Heinzelmann; Kathleen M. Kelleher; Joseph Kvedar; Rithy Chau  
**Cc:** Ed & Laurie Bachrach; Bernie Krisher; Noun SoThero; Fil B. Tabayoyong  
**Subject:** Rattanakiri provincial hospital TM clinic patient HM#00123

Dear All,

Here is the patient HM# 00123 and his photos.

Best regards,  
Channarith

**Rattanakiri Provincial Hospital Telemedicine Clinic with  
Sihanouk Hospital Center of HOPE and Partners in Telemedicine**

**Patient:** HM# 00123 from village I, Labanseak, Ratanakiri

**Chief Complaint:** Chest pain, palpitation, SOB on exertion, weakness



**HPI:** 28 male with PHM of heart problem about 1 year, has been diagnosed and treated by private clinic with unknown drugs, presented with chest pain, palpitation, SOB on exertion and weakness about 3 month, the chest pain always occur when he run or play sport and associate with sob and palpitation. he said, during 3 month he could not play sport(football) as he had used to play before and he always went to the clinic for help. no cough, no fever, no N/V.

**PMH/SH:** Heart Problem

**Social Hx:** single, no smoke, no drink

**Allergies:**

**Family Hx:** His mother has HTN

**ROS:** poor sleeping, headache, weakness

**PE:**

**Vital Signs:** BP140/90mmhg P64/mn R24/mn T36.5 Wt

**General:** look stable

**HEENT:** no sore throat, no jugular vessel distention

**Chest:** Lung: clear both sides, Heart: irregular of rhythm( 54 - 68/mn), systolic murmur in tricuspid area

**Abdomen:** soft, flat, + BS all quadrant, no HSM

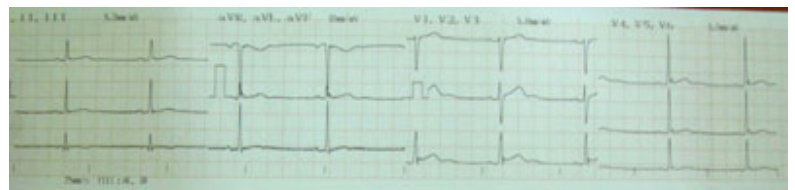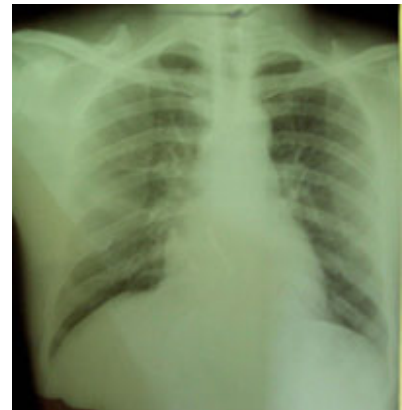**Musculoskeletal:** unremarkable

**Neuro:** alert

**GU:** not done

**Rectal:** not done

**Previous Lab/Studies:**



**Lab/Studies Requests:** calcium: 9.4mg/dl, cholesterol: 154mg/dl, creatinine: 1.2mg/dl, triglycerides:239.0mg/dl  
EKG show left ventricular hypertrophy

**Assessment:** cardiac insufficiency? Cardiac Hypertrophy? Anterior myocardial Ischemia ?

**Plan:** Atenolol 50mg: ½ tab bid  
Aspirine 300mg in the morning after breakfast  
low salt and fat diet

**Comments/Notes:**

**Examined by:** Dr. Sam Baramey **Date:** 23/06/2005

Please send all replies to [kirihospital@yahoo.com](mailto:kirihospital@yahoo.com) and cc: to [tmed\\_rithy@online.com.kh](mailto:tmed_rithy@online.com.kh) .

*The information transmitted in this e-mail is intended only for the person or entity to which it is addressed and may contain confidential and/or privileged material. Any review, retransmission, dissemination or other use of or taking of any action in reliance upon, this information by persons or entities other than the intended recipient is prohibited. If you received this e-mail in error, please contact the sender and delete material from any computer.*

**From:** Jack Middlebrooks [mailto:jmiddleb@camnet.com.kh]

**Sent:** Friday, June 24, 2005 8:48 AM

**To:** 'Kiri Hospital'; 'Rithy Chau'; 'Brian Hammond'; 'Paul Heinzelmann'; 'Kathleen M. Kelleher'; 'Joseph Kvedar'; 'Rithy Chau'

**Cc:** 'Ed & Laurie Bachrach'; 'Bernie Krisher'; 'Noun SoThero'; 'Fil B. Tabayoyong'

**Subject:** RE: Rattanakiri provincial hospital TM clinic patient HM#00123

Dear Dr. Baramey:

My two highest considerations for this patient are (1) arrhythmia (2) valvular heart disease.

While you note that the patient has an irregular pulse on exam, the ECG appears to have a regular rhythm. It would be very helpful to obtain an ECG while the patient has symptoms of palpitations-- can you ask the patient perform an activity that causes palpitations in the clinic and then obtain an ECG?

The patient's bradycardia is also significant. Is he currently taking any medications that could cause a slow heart rate (beta-blocker, Ca channel blocker, digoxin?)

It is possible that the patient has valvular heart disease which is causing an arrhythmia. The best way to diagnosis this is by echocardiography, which I would recommend if at all possible for the patient. Hypertrophic obstructive cardiomyopathy (HOCM) can also cause (potentiall fatal) arrhythmias in young men during sports and can only be diagnosed by echocardiography.

If the patient really has heart rates as low as 54, as you report in your note, I would not recommend adding atenolol until the diagnosis is more clear. I think your plan for aspirin is fine.

I hope this is helpful.

With best regards,

Jack

**From:** Kiri Hospital [mailto:kirihospital@yahoo.com]  
**Sent:** Thursday, June 23, 2005 5:25 PM  
**To:** Rithy Chau; jmiddleb@camnet.com.kh; Brian Hammond; Paul Heinzelmann; Kathleen M. Kelleher; Joseph Kvedar; Rithy Chau; Cornelia Haener; Ruth Tootill  
**Cc:** Ed & Laurie Bachrach; Bernie Krisher; Noun SoThero; Fil B. Tabayoyong  
**Subject:** Rattanakiri provincial hospital TM clinic patient DS#00124

Dear All,

Here is the patient DS#00124 and her photos .

Best regards,

Channarith

---

**Rattanakiri Provincial Hospital Telemedicine Clinic with  
Sihanouk Hospital Center of HOPE and Partners in Telemedicine**



**Patient:** DS# 00124 from village I, labanseak, Bunlung, Ratanakri Province

**Chief Complaint:** upper extremities tremor, anterior neck mass and anterior neck tension and headache

**HPI:** 24 female with MPH of nodular goiter about 4 years, has been diagnosed by physician in Vietnam, presented with upper extremities tremor, anterior neck mass and anterior neck tension and headache about 6 months, she indicated that her anterior neck mass had begun with a small size without symptoms to notice after that it had been increasing its size every year and at last 6 months the symptoms of upper extremities tremor, anterior neck mass and anterior neck tension and sometime have palpitation have been presenting. no chest pain, no cough, no N/V, no weight loss.

**PMH/SH:** small nodular goiter

**Social Hx:** Married no child, no smoke, no drink

**Allergies:**

**Family Hx:** Her mother has HTN

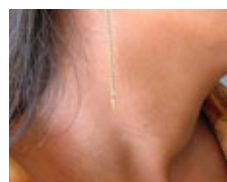**ROS:** poor sleeping, good appetite, headache, feel sore throat and difficult to swallow when cold weather

**PE:**

**Vital Signs:** BP120/80mmhg P84/mn R 20 T36.7 Wt

**General:** look stable

**HEENT:** Anterior neck mass about 3x4 cm, upper extremities tremor



**Chest:** Lung: clear both sides, Heart: RRR, no murmur

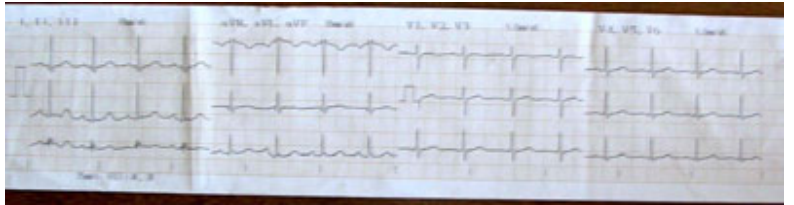
**Abdomen:** soft, flat, no tender, no HSM

**Musculoskeletal:** extremities tremor

**Neuro:** alert

**GU:** not done

**Rectal:** not done



**Previous Lab/Studies:**

**Lab/Studies Requests:** EKG

**Assessment:** Nodular Goiter

**Plan:** T3, T4, TSH

**Comments/Notes:** Could I draw her blood and send to Center of Hope for T3, T4, TSH test?

**Examined by:** Dr. Sam Baramy      **Date:** 23/06/2005

Please send all replies to [kirihospital@yahoo.com](mailto:kirihospital@yahoo.com) and cc: to [tmed\\_rithy@online.com.kh](mailto:tmed_rithy@online.com.kh) .

*The information transmitted in this e-mail is intended only for the person or entity to which it is addressed and may contain confidential and/or privileged material. Any review, retransmission, dissemination or other use of or taking of any action in reliance upon, this information by persons or entities other than the intended recipient is prohibited. If you received this e-mail in error, please contact the sender and delete material from any computer.*

**From:** Jack Middlebrooks [mailto:jmiddleb@camnet.com.kh]

**Sent:** Friday, June 24, 2005 9:09 AM

**To:** 'Kiri Hospital'; 'Rithy Chau'; 'Brian Hammond'; 'Paul Heinzelmann'; 'Kathleen M. Kelleher'; 'Joseph Kvedar'; 'Rithy Chau'; 'Cornelia Haener'; 'Ruth Tootill'

**Cc:** 'Ed & Laurie Bachrach'; 'Bernie Krisher'; 'Noun SoThero'; 'Fil B. Tabayoyong'

**Subject:** RE: Rattanakiri provincial hospital TM clinic patient DS#00124

Dear Dr. Baramy:

I agree with your plan.

Jack

**From:** Fiamma, Kathleen M. [mailto:KFIAMMA@PARTNERS.ORG]

**Sent:** Saturday, June 25, 2005 1:57 AM

**To:** kirihospital@yahoo.com

**Cc:** tmed\_rithy@online.com.kh

**Subject:** FW: Rattanakiri provincial hospital TM clinic patient DS#00124

-----Original Message-----

**From:** Tan, Heng Soon, M.D.

**Sent:** Friday, June 24, 2005 2:22 PM

**To:** Fiamma, Kathleen M.

**Subject:** RE: Rattanakiri provincial hospital TM clinic patient DS#00124

Yes, sending thyroid tests to check status makes sense. She is likely euthyroid by history and exam despite tremors. However I'm more concerned about the nodular goiter. If the thyroid contains multiple nodules, then Hashimoto's goiter is likely. If only a single nodule is present, then the differential diagnosis includes a colloid cyst vs thyroid cancer vs thyroid adenoma. Thyroid ultrasound can distinguish between cyst and solid nodule. Thyroid radioactive iodine uptake and imaging can distinguish between a cold [cancer or adenoma] and hot [toxic] nodule. Fine needle aspiration will collapse a cyst. Aspiration cytology may distinguish between malignancy vs benign adenoma, but cytological interpretation is a challenge to the pathologist. She should be referred to the hospital for these studies.

Heng Soon Tan, M.D.

---

**Friday, June 24, 2005**

---

### **Follow-up Report for Rattanakiri TM Clinic**

There were 5 new and no follow up patient seen during this month TM clinic at Rattanakiri Referral Hospital (RRH). The data of all new cases were transmitted and received replies from both Phnom Penh and Boston. Per advice sent by Partners in Boston and Phnom Penh Sihanouk Hospital Center of HOPE, the following patients were managed and treated per local staff:

[Please note that in general the practice of dispensing medications at RRH for all patients is usually limited to a maximum of 7 days treatment with expectation of patients to return for another week of supplies if needed be. This practice allows clinicians to monitor patient compliance to taking medications and to follow up on drug side effects, changing of medications, new arising symptoms especially in patients who live away from the town of Banlung and/or illiterate.]

---

### **Treatment Plan for Rattanakiri TM June 2005**

#### **1. TR#00120, 36M, Village I**

Dx: 1. TB arthritis

Tx: 1. anti-TB drugs by guideline of MOH  
2. Paracetamol 500mg 1 tab po bid prn

#### **2. CL#00121, 31F, Village III**

Dx: 1. Goiter

Tx: 1. Check free T4 and TSH at SHCH in PP

3. **CL#00122, 33F, Village III**

Dx: 1. Goiter

Tx: 1. Check free T4 and TSH at SHCH in PP

4. **HM#00123, 28M, Village I**

Dx: 1. Arrhythmia    2. VHD    3. Hypertrophic Obstructive Cardiomyopathy??

Tx: 1. 2D Cardiac echo at Calmette Heart Center in PP  
2. ASA 500mg ¼ tab po qd

5. **DS#00124, 24F, Village I**

Dx: 1. Goiter

Tx: 1. Check free T4 and TSH at SHCH in PP (patient did not show up for appointment for bloodwork)

**From:** Rithy-chau [mailto:tmed\_rithy@online.com.kh]

**Sent:** Thursday, June 30, 2005 4:22 PM

**To:** Rattanakiri TM (kirihospital@yahoo.com)

**Cc:** Bernie Krisher (bernie@media.mit.edu); Fil - Jr. Tabayoyong (docfil@yahoo.com); Gary Jacques (gjacques@online.com.kh); Jack Middlebrooks (jmiddleb@camnet.com.kh); Ed & Laurie Bachrach (lauriebachrach@yahoo.com); Ly Channarith (ly\_channarith@yahoo.com); So Thero Noun (thero@cambodiadaily.com); HealthNet Rattanakiri (healthni@camintel.com)

**Subject:** Results for Patients CL#00121 and CL#00122

Dear Dr. San and Channarith,

Here are the results for thyroid function tests on 27/06/05 for two patients you sent recently from your June 2005 TM Clinic:

1. CL#00121, 31F, Village III
  - a. TSH                    0.72                    [0.49 – 4.67]
  - b. Free T4                14.79                   [9.14 – 23.81]

Interpretation: Euthyroid

Recommendation: If patient is stable without significant sx, may check her TSH again in 6 months. Otherwise, follow her up next TM clinic.

2. CL#00122, 33F, Village III
  - a. TSH                    0.33                    [0.49 – 4.67]
  - b. Free T4                16.11                   [9.14 – 23.81]

Interpretation: Subclinical hyperthyroidism



Recommendation: If patient is stable without significant sx, may check her TSH again in 2 months. Otherwise, follow her up next TM clinic.

From previous month TM Clinic, thyroid function tests on 05/06/05:

- 3. KL#00119, 32F, Village IV
  - a. TSH 0.46 [0.49 – 4.67]
  - b. Free T4 13.45 [9.14 – 23.81]
  - c. Tot T3 1.52 [0.78 – 2.5]

Interpretation: Subclinical Hyperthyroidism

Recommendation: If patient is stable without significant sx, may check her TSH again next month with follow-up on next TM clinic.

Rithy/Jack

---

**From:** Rithy-chau [mailto:tmed\_rithy@online.com.kh]

**Sent:** Thursday, July 07, 2005 11:27 AM

**To:** Rattanakiri TM

**Cc:** Bernie Krisher; Ed & Laurie Bachrach; Fil - Jr. Tabayoyong; Gary Jacques; Jack Middlebrooks; Ly Channarith; HealthNet Rattanakiri; So Thero Noun

**Subject:** Follow-up Report for Rattanakiri TM Patients

**Dear Dr. San and Channarith,**

**Here is the follow-up report on two patients from Rattanakiri TM clinic and please ask them to return for f/u during our next TM clinic in July:**

**I. HS#00123, 28M, Village I**

Dx: 1. Anxiety 2. Tension HA

Tx: Patient was diagnosed during Rattanakiri TM Clinic June 2005 with possible cardiac insufficiency, cardiac hypertrophy, and/or anterior MI. The patient reported to have a history of “heart problem” presenting with CP, SOB, palpitation and weakness for 3 months. The sx seemed to associated with playing sport. His BP 140/90, P 64, R 24, T 36.5 and “look stable.” “EKG show left ventricular hypertrophy,” chol=154mg/dL and TG=239mg/dL. Cardiac exam was reported to have “irregular rhythm( 54 – 68/mn), systolic murmur in tricuspid area”. As a result, this patient was recommended to have a 2D cardiac echo done at Calmette Heart Center in Phnom Penh. The result was negative for any cardiac abnormality or malfunction as reported on 5/7/05. PA Rithy saw the patient on 5/7/05 at SHCH, confirmed the 2D echo report with Dr. Sophal. At SHCH, the patient was briefly interviewed again with a PMH of head injury (which required minor stitching of a scalp laceration and recovered uneventfully) about 2 years ago that seemed to cause him to be quite nervous and fearful of serious consequences of losing memories or worse when ever he experienced an occasional HA off and on since. The palpitation, chest pressure which seemed to make his left side of the body “feeling heavy” and thus producing SOB were noticed (by the patient) to appear mainly after the HA. The feeling of weakness came after each episode and caused him to worry more about his health and unable to sleep well. He consulted several care providers in Banlung, Rattanakiri, and was

told that he has “some sort of heart problem which one (doc) said the heart is getting small and other said it is getting big.” Because the medications prescribed (at private clinics) were not effective for helping his conditions, he came to the TM clinic. On examination, patient was A&Ox4, look healthy and stable, not obese; VS normal, chest was CTA and HRRR with remote skip beat (auscultated for 5 minutes) without murmur; abdomen not exam since no GI complaint. An EKG was repeated with reading of normal sinus rhythm and HR=65, non-specific ST changes, and no PVC or LVH. In conclusion, the patient was given a dx of tension HA and anxiety. Counseling on trying different things to overcome his fear (from the head injury and dx of heart problem given previously) was given and patient was asked to continue to do sport and aerobic exercise as well as eating low fat diet. Patient was asked to take his result and follow-up report to his doctor at RRH and medication (paracetamol prn) can be obtained there also. Dr. Jack confirmed this plan with PA Rithy.

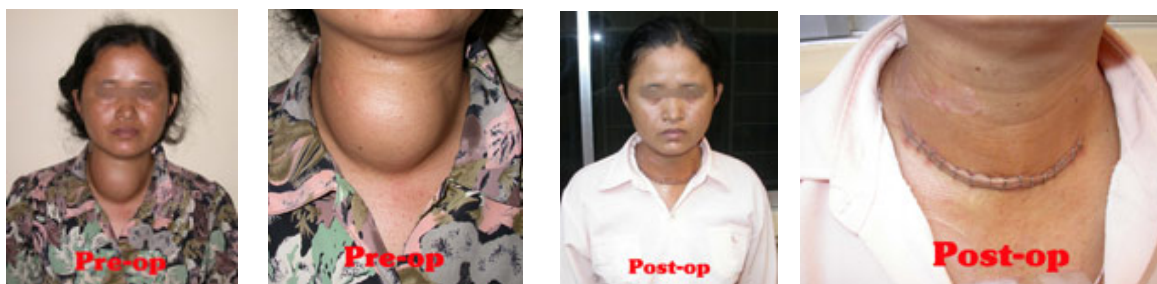## II. KO#00110, 38F, Sre Ang Krang Village

Dx: 1. Euthyroid Cystic/Multinodular Goiter

Tx: Patient was scheduled by Senior Surgeon at SHCH, Dr. Cornelia Haener, for consultation at the surgical clinic on Wednesday, May 4, 2005. The SHCH surgeon evaluated and diagnosed her with multinodular goiter and scheduled for a subtotal thyroidectomy to be admitted on 11/5/05 and underwent the procedure on 12/5/05 per Dr. Phot and Surgical Director, Dr. Ruth Tootill. The procedure included right total thyroidectomy with resection of inferior pole of the left lobe and it was uneventful for the patient. She recovered well and was discharged (per Surgeon, Dr. Tholy) on Tuesday, May 17, 2005, with instructions on wound care and pain control medications paracetamol/codeine prn. Patient will be followed at RRH for suture removal on 22/5/05.

Histology of the tumor was sent to SHCH pathology lab and the final pathology report on 27/5/05 was concluded to be thyroid follicular adenoma.

Regards,  
Rithy



---

**The next Rattanakiri TM Clinic will be held on  
July 19-20, 2005**